



CASE STUDY DETAILS

PATIENT NAME: Reggie

WEIGHT: 52 lbs

AGE/SEX: 12 y / Male

BREED: Retired Working Border Collie

CONDITION: Periodontal disease with horizontal and vertical bone loss.

TREATMENT: Stimulation of bone growth with Osteoallograft™ Periomix™

SURGEON: Judith E. Yee, DVM, Diplomate AVDC

Dept of Dentistry and Oral Surgery

Desert Veterinary Specialists

Palm Desert, CA

TYPE OF GRAFT USED:

- Osteoallograft™ Periomix™

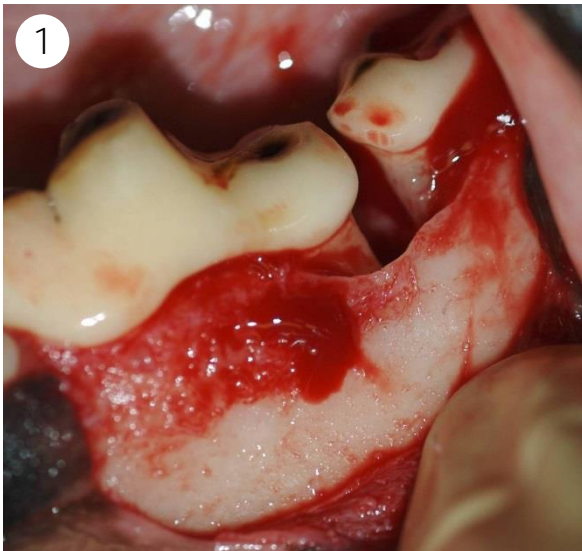


Figure 1: Surgical flap is created. Periodontal disease caused a marked degree of bone loss that generally requires extraction.

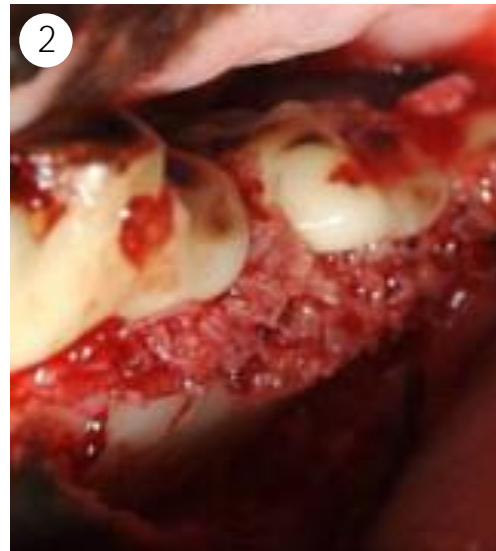

Figure 2: Mixed with patient blood, the Osteoallograft Periomix forms a granular paste that conforms well to the surgical site.

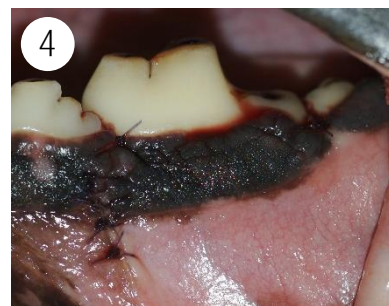

Figure 3: Osteoallograft Periomix.
Figure 4: Surgical flap is sutured closed.

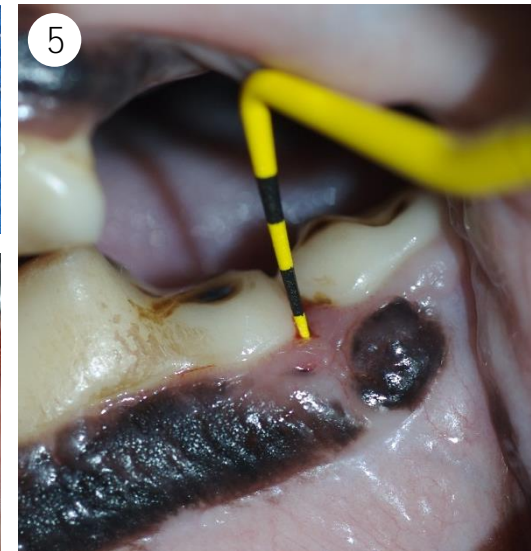
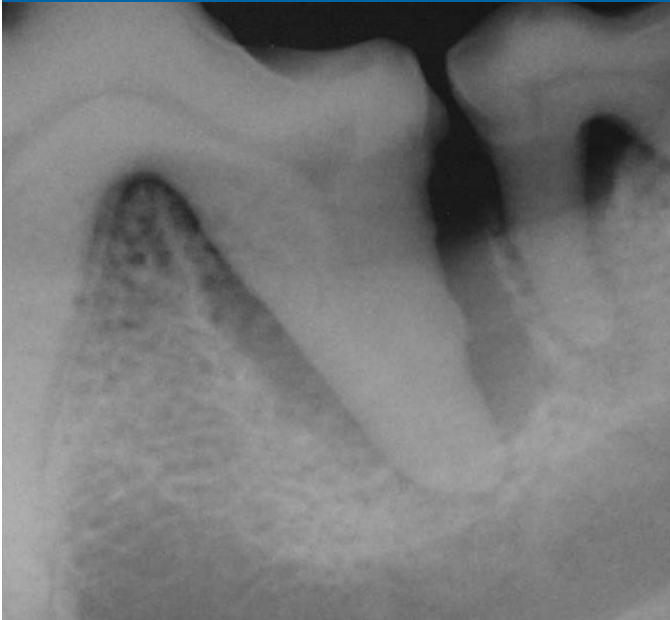
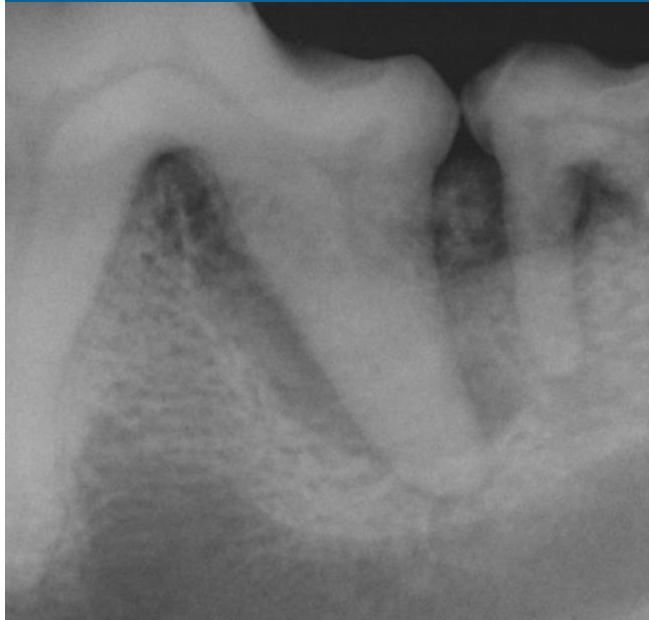
Figure 5: Follow-up at 8 weeks. Reconstruction of periodontium to 2 mm probing depth has occurred and extraction has been avoided.

PRE - OP



IMMEDIATE POST - OP



Save teeth instead of extracting
with VTS PERIOMIX



12 yr Border Collie:

Severe vertical and horizontal bone loss
Owner only willing to brush for 2 months

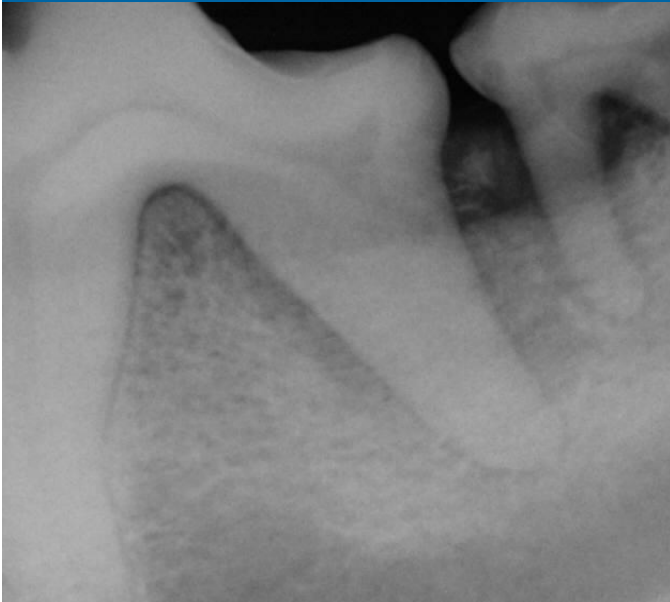at 2 months

Reconstruction of periodontium and
restoration of crestal bone.

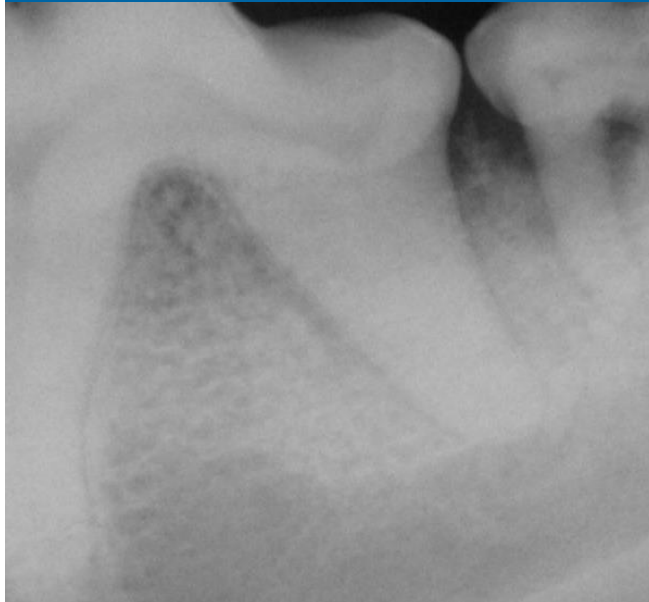at 32 months (2.6 years)

Alveolar ridge height maintained long-term.
Teeth have been
preserved without brushing.

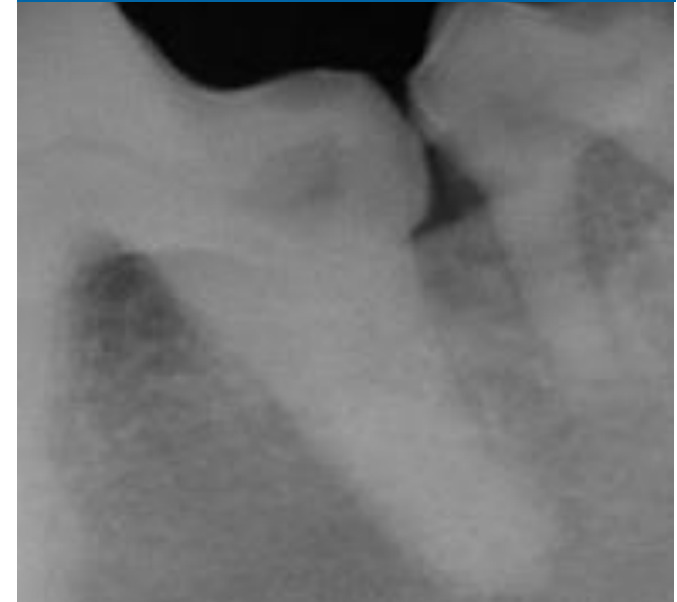
FOLLOW - UP AT 4 WEEKS



FOLLOW - UP AT 8 WEEKS



FOLLOW - UP AT 32 MONTHS



Patient Name: Reggie

Weight: 52 lbs

Age/Sex: 12 y / Male

Breed: Working Border Collie

Bone graft for this case study provided by Veterinary Transplant Services, Inc. For more information about bone grafts, please call VTS at 1-800-558-5223 or visit us at www.vtsonline.com.